

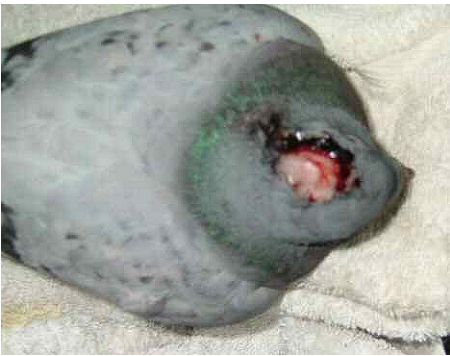How to treat a scalped pigeon

The sight of a pigeon that has had its scalp torn back, often exposing the bone, is shocking.

Will a scalped pigeon survive? Yes! And treatment is very simple.

Here are some case histories:

Winnie the Pooh is a racing pigeon that was found



huddled in a taxi rank in the city centre in November 2005.

She must have been hit by a car because had been scalped, was unable to use one wing and her beak wobbled alarmingly when touched.

Initially I treated her for shock by warming her on a heat pad for half an hour, then giving her rehydrating solution (1 pint warm water mixed with 1/2 tablespoon glucose, or honey or - if they are not available sugar and 1/2 teaspoon salt) and I also gave her 2 drops of metacam for cats in the bottom of the lower beak for the pain. Then I washed the wound with sterile saline (that can be made at home by mixing a spoon of salt salt with boiling water and allowing it to cool) and smeared on [Intrasite gel](#) which I bought from the local chemist (now I would use F10 antigermicidal barrier cream) over the wound to keep it moist and allow it to heal without scabbing over which would have caused problems.


I gave her a 7 day course of an amoxycillin/clavunate combination antibiotic (brands available in the UK are Synulox, Clavaseptim, Noroclav) which I obtained from my vet.



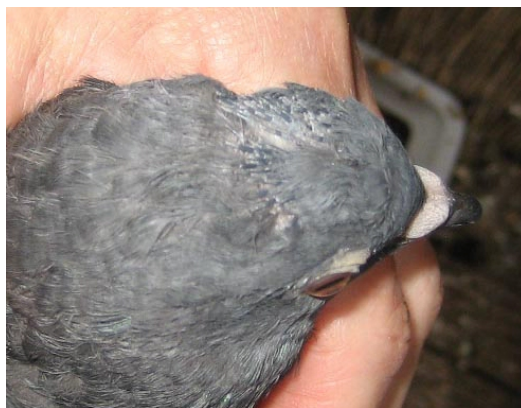Winnie's
about 4 months to grow back.

skull healed quickly but the feathers took

This is Winnie in nearly six years later. Only a small scar remains at the site of the injury.

Moonshine was only a baby in the nest when he was rescued from a ledge in a town centre in mid April 2011.  He must have been scalped some days earlier as the skin around the scalped area had dried into a ridge.

This time I used F10 Germicidal barrier ointment, smearing it on his head every time I fed him, which was 4 times a day. I also treated him with a course of Synulox in case there was an infection. The ointment softened the tissues and kept the wound moist. Because Moonshine was only a baby he healed very quickly.



This is Moonshine 6 weeks later:

The photos show the new feathers growing.



By the time Moonshine was an adult there was no evidence of the scalping.